

**CASE REPORT**

Hybrid minimally invasive technique with the bidirectional rotational Evolution[®] mechanical sheath for transvenous lead extraction: A collaboration between electrophysiologists and cardiac surgeons

Federico Migliore MD, PhD | Giacomo Cavalli MD | Tomaso Bottio MD, PhD |
Martina Testolina MD | Manuel De Lazzari MD, PhD | Emanuele Bertaglia MD, PhD |
Sabino Iliceto MD | Gino Gerosa MD

Department of Cardiac, Thoracic, and Vascular Sciences, University of Padova, Padova, Italy

Correspondence

Federico Migliore, Department of Cardiac, Thoracic, and Vascular Sciences, University of Padova, Padova, Italy.
Email: federico.migliore@libero.it

Abstract

We report a case of a 63-year-old man referred for lead extraction with the bidirectional rotational Evolution[®] RL mechanical sheath because of systemic infection. As it was judged a “high-risk” procedure, we opted for a “hybrid,” minimally invasive approach consisting in a minithoracotomy access. This technique is a feasible approach, and it might be a potential safer alternative in the most challenging transvenous lead extraction procedures.

KEYWORDS

cardiac electronic devices, Evolution RL, implantable cardioverter-defibrillator, lead extraction, minimally invasive thoracotomy

1 | INTRODUCTION

Transvenous lead extraction (TLE) is a challenging procedure and is associated with potential life-threatening complications.¹ Therefore, safety is an essential clinical endpoint when physicians decide to perform TLE, especially in “high-risk” patients.

There is no an universal agreement on the definition of “high-risk” patient. However, there are several established patient and lead characteristics, including age, systemic infection, dwell time, number of extracted leads, use of implantable cardioverter-defibrillator (ICD) leads, use of dual-coil ICD leads, and the presence of passive-fixation mechanisms influencing the outcome of the procedure, the degree of complications and associated mortality.¹⁻⁴

Recently, to avoid traditional open-chest surgical technique, a “hybrid” approach has been proposed for challenging TLE in a small patient series.⁵ This approach allows direct visualization of the critical area of potential vascular injury during TLE

maneuvers and prompts surgical treatment in case of serious complications.

We report a modified “hybrid” minimally invasive approach for a challenging TLE with the bidirectional rotational Evolution[®] RL mechanical sheath (Cook Medical, USA) in a high-risk patient with systemic infection.

2 | CASE REPORT

We report a case of a 63-year-old man referred for TLE because of systemic infection and refractory heart failure (HF). In November 2004, he underwent cardiac resynchronization therapy device implantation with a double coil, active fixation defibrillator lead (Boston Scientific, Endotak Reliance 0158) in the right ventricle (RV), a passive-fixation atrial lead (Boston Scientific, Finline II Sterox 4480) in right atrial appendage (RAA), and a passive-fixation lead in a

This is an open access article under the terms of the Creative Commons Attribution-NonCommercial License, which permits use, distribution and reproduction in any medium, provided the original work is properly cited and is not used for commercial purposes.

© 2018 The Authors. *Journal of Arrhythmia* published by John Wiley & Sons Australia, Ltd on behalf of the Japanese Heart Rhythm Society.

branch of the coronary sinus (Figure 1A). The patient was also evaluated for left ventricular assist device (LVAD) implantation after TLE and complete resolution of infection.

After a multidisciplinary evaluation, the TLE was judged a “high-risk” procedure considering the severe LV dysfunction, the concomitance of severe chronic obstructive pulmonary disease, the systemic infection, and technical lead parameters.^{1–4} Thus, we agreed that the patient could benefit from a “hybrid” TLE approach avoiding an open-chest surgical technique.

The procedure was performed in a hybrid operating room under general anesthesia, with invasive blood pressure monitoring and using transesophageal echocardiographic guidance. Contrast venography showed important adherences at the left subclavian and superior vena cava. The leads were disconnected and prepared for lead extraction with locking stylets (Liberator, Cook Medical, USA).

Simultaneously, a minithoracotomy access, with a 4 cm incision at the right anterior portion of the 2th intercostal space, was performed by the cardiac surgeon, followed by a pericardial opening with direct visualization of the critical area for potential vascular injury during TLE maneuvers, including the superior vena cava (SVC), the cava–right atrial junction of the right atrium and the RAA (Figure 1B,C,D, Video S1).

After several attempts and adjustments, using a 11Fr Evolution[®] RL Shortie first and then a 13Fr Evolution[®] RL sheath with an outer

sheath (SteadySheath[®] Evolution[®] Tissue Stabilization Sheath, Cook Medical, USA), we were able to advance into the left subclavian vein (Figure 1C) and into the SVC. Tenacious fibrotic adherences were gradually cut, and the leads were extracted through the sheath without any complications. A temporary RV bipolar lead was implanted through the right axillary vein (Figure 2A,B).

After complete resolution of the infection, the patient underwent LVAD (Jarvik 2000, Jarvik Heart, New York) implantation for refractory HF and epicardial PM implantation. After 2 months of follow-up, the incisions healed cleanly, the LVAD and the PM were functioning properly.

3 | DISCUSSION

Injury to the SVC, though uncommon, is the worst and potentially fatal complications of TLE occurring in approximately 0.5% of procedures with a high mortality rate (50%). Thus, prompt injury recognition and hemostasis are crucial, as delays of more than 5–10 minutes from time of injury to opening the chest are associated with an increased risk of mortality.¹

A recent prospective multicenter registry (ELECTRa study) of consecutive TLE procedures, showed that independent predictors of procedure-related major complications, of clinical failure and of all-

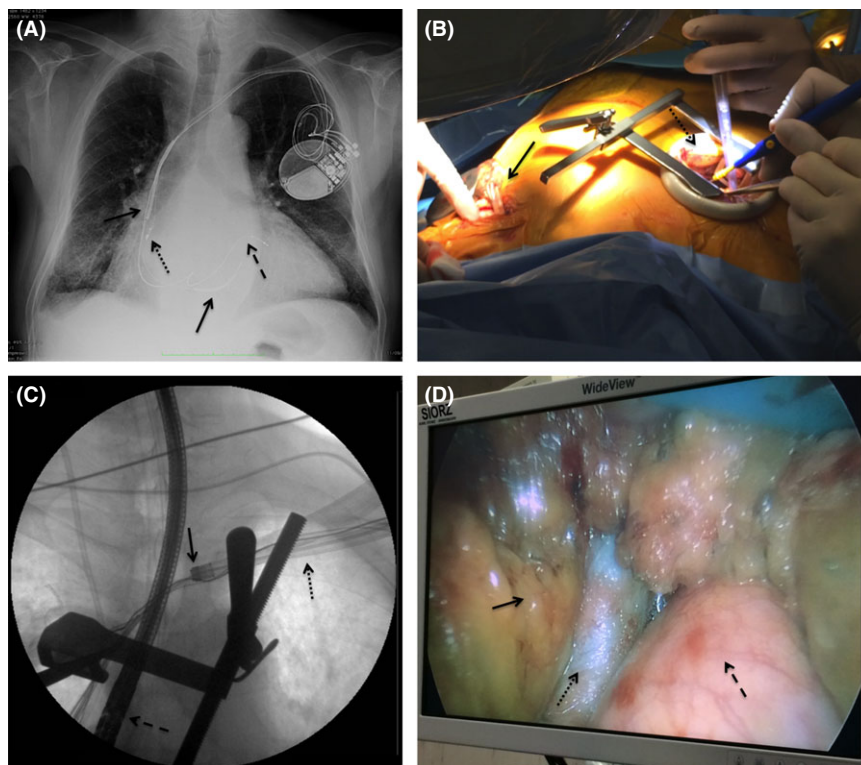


FIGURE 1 Preoperative chest X-ray showing double coil right ventricular lead (black line), passive-fixation atrial lead (dotted line), and coronary sinus lead (dashed line) (Panel A). Operatory view: device remove (black line) and preparation of the right anterior minithoracotomy for direct visualization of the critical area for potential vascular injury during transvenous lead extraction (Panel B). Intraoperative fluoroscopy view: Cook medical Evolution RL sheath tip (black line), steady outer sheath (dotted line), and transesophageal echocardiography (dashed line) (Panel C). Direct surgical view of lung (black line), superior vena cava (dotted line), and ascending aorta (dashed line) (Panel D)

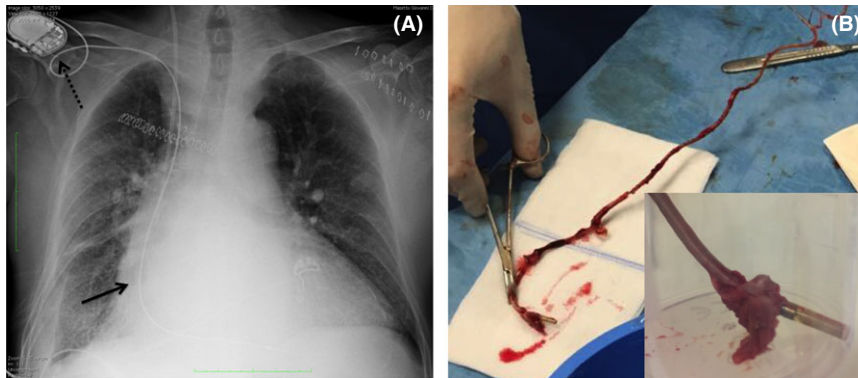


FIGURE 2 Chest X-ray after lead extraction showing a temporary right ventricular lead (black line) inserted via the right axillary vein, and the external pulse generator (dotted line) (Panel A). Right ventricular extracted lead. Of note, the presence of important fibrous material adherent to the lead (Panel B)

cause mortality are multivariate and not only related to the patient (old age, female gender, NYHA class, and systemic infection) and lead profile (prolonged dwell time, multiple leads), but also to the requirement for powered sheath, femoral approach, center experience, and procedure volumes.² Concerning long-term survival despite effective TLE, predictors of a worse prognosis are renal failure, presence of “ghosts” at post-TLE transesophageal echocardiography and “closed” implantable device-related infection of the pocket.⁶ Therefore, it is evident as the correct identification of a “high-risk” patient has important implications regarding decision-making and therapeutic strategies in patients who are candidates for TLE.

Despite the advent of new TLE techniques has greatly diminished the need of an open surgical removal of leads, a surgical approach can be still required. Goyal et al⁷ provided the first single-center experience of a hybrid approach consisting of simultaneous transvenous laser extraction with minimally invasive right thoracotomy and using cardiopulmonary bypass (CPB).

Recently, Bontempi et al⁵ reported a “hybrid” approach with minithoracotomy or thoracoscopic avoiding the routine use of CPB, for procedures considered to be at high risk in order to avoid open-chest surgical technique.

We report a case of a “hybrid” TLE approach with minithoracotomy access. Compared to the technique described by Bontempi et al,⁵ we performed a small incision at the right anterior portion of the 2th intercostal space instead of the 4th fourth intercostal space. We believe that this minimal difference in the approach can allow a better direct visualization of the critical area for potential vascular injury during TLE maneuvers, such as, the SVC the right atrial junction and the RAA without exposing the patient to higher surgical risk and without interfering with electrophysiologist’s team due to the proximity of the surgical incision to the pocket site.

The potential advantages of the hybrid technique may be counterbalanced by a possible approach-related thoracic complication including wound infection and dehiscence.

However, we believe that the advantage of a direct visualization of vascular structures and of prompt surgical treatment of potential

life-threatening complications not only in case of manifest vascular injury but also treating impending ruptures with a minimally invasive approach goes beyond possible potential approach-related complications. To this regard, Bontempi et al⁵ described 2 cases of impending rupture that was avoided by transiently interrupting the extraction procedure while repairing the site of vascular tear, either at the level of the RA of the SVC and at the junction with brachiocephalic vein.

A thoracoscopic access has been also proposed.⁵ However, in our opinion, the thoracoscopic technique could have few potential limitations: (i) It may not allow a complete direct visualization of the critical area for potential vascular injury during TLE; (ii) it may not allow adequate treatment of vascular damage, resulting in conversion into thoracotomy and therefore delayed in surgical treatment.

A potential limitation of the hybrid approach could be the treatment of a brachiocephalic or subclavian vein injury. However, it is rare, and the worst and potentially fatal complication of TLE is the injury of the SVC.

In addition, this is the first report of a hybrid minimally invasive technique for TLE using the bidirectional rotational Evolution[®] mechanical sheath (Cook Medical, USA). To this regard, it has been recently reported that the new Evolution mechanical sheath is an effective and safe tool for the extraction of chronically implanted leads when advanced techniques are required.⁸

Recently, a new tool for lead extraction (Bridge, Spectranetics, Colorado Springs, CO) aims to reduce the lethality of vascular injuries by providing rapid temporary endovascular occlusion of the SVC.⁹ However, clinical experience is limited by only few cases and for tears that occur in the RA or RV is unlikely to provide tamponade. Moreover, in case of vascular damage, the surgeon’s intervention is necessary in any case.

Although the need to provide direct visualization of the critical area during TLE procedures in higher risk cases are unclear and an optimal approach for this is uncertain, our findings confirmed and extended previous observations⁵ by showing that an “hybrid” approach is feasible and it might provide more safety in challenging procedures because it allows monitoring of vascular integrity and prompt treatment of injury. Further information about the utility of

such surgical approaches should be included in lead extraction registries to provide guidance in the future.

ACKNOWLEDGEMENTS

Many thanks to M.T. (Cook Medical, USA) for his important technical support.

CONFLICT OF INTEREST

Authors declare no conflict of interests for this article.

ORCID

Federico Migliore  <http://orcid.org/0000-0001-8574-9421>

REFERENCES

1. Hauser RG, Katsiyannis WT, Gornick CC, Almquist AK, Kallinen LM. Deaths and cardiovascular injuries due to device-assisted implantable cardioverter- defibrillator and pacemaker lead extraction. *Europace*. 2010;12:395–401.
2. Bongiorni MG, Kennergren C, Butter C, et al. The European lead extraction ConTRolled (ELECTRa) study: a European heart rhythm association (EHRA) registry of transvenous lead extraction outcomes. *Eur Heart J*. 2017;38:2995–3005.
3. Bontempi L, Vassanelli F, Cerini M, et al. Predicting the difficulty of a transvenous lead extraction procedure: validation of the LED index. *J Cardiovasc Electrophysiol*. 2017;28:811–8.
4. Mazzone P, Tsiachris D, Marzi A, et al. Predictors of advanced lead extraction based on a systematic stepwise approach: results from a high volume center. *Pacing Clin Electrophysiol*. 2013;36:837–44.
5. Bontempi L, Vassanelli F, Cerini M, et al. Hybrid minimally invasive approach for transvenous lead extraction: a feasible technique in high-risk patients. *J Cardiovasc Electrophysiol*. 2017;28:466–73.
6. Diemberger I, Biffi M, Lorenzetti S, et al. Predictors of long-term survival free from relapses after extraction of infected CIED. *Europace*. 2017. [Epub ahead of print].
7. Goyal SK, Ellis CR, Ball SK, et al. High-risk lead removal by planned sequential transvenous laser extraction and minimally invasive right thoracotomy. *J Cardiovasc Electrophysiol*. 2014;25:617–21.
8. Mazzone P, Migliore F, Bertaglia E, et al. Safety and efficacy of the new bidirectional rotational Evolution[®] mechanical lead extraction sheath: results from a multicentre Italian registry. *Europace*. 2017. [Epub ahead of print].
9. Boyle TA, Wilkoff BL, Pace J, Saleem M, Jones S, Carrillo R. Balloon-assisted rescue of four consecutive patients with vascular lacerations inflicted during lead extraction. *Heart Rhythm*. 2017;14:757–60.

SUPPORTING INFORMATION

Additional Supporting Information may be found online in the supporting information tab for this article.

How to cite this article: Migliore F, Cavalli G, Bottio T, et al. Hybrid minimally invasive technique with the bidirectional rotational Evolution[®] mechanical sheath for transvenous lead extraction: A collaboration between electrophysiologists and cardiac surgeons. *J Arrhythmia*. 2018;00:1–4.
<https://doi.org/10.1002/joa3.12064>